THE CLEATOR CLINIC
#310-943 West Broadway,
Vancouver, B.C. V5Z 4E1
tel: 604-681-1513
fax: 604-681-1517
email: icleator@telus.net
www.haemorrhoids.ca

External hemorrhoids

These can be confused with prolapsed internal hemorrhoids but strictly speaking an external hemorrhoid is a hemorrhoid in the external hemorrhoidal plexus (figure 2). These can develop clot(s) in them about the size of a pea and if seen within 24 to 48 hours of onset, pain relief is prompt with injecting 2ml of 2% Xylocaine® as anesthetic, incising over the clot and expelling it. EMLA® cream is prescribed for the patient Q8H and the patient is advised that there will be pain for two or three days with discharge of some blood and fluid. Diet as usual and showers for 3 days and baths after that are the recommendations. In emergency departments, this is a common procedure and often a thrombosed internal hemorrhoid is mistaken for this and incised with a lot of later pain and bleeding for the patient.

Fig. 2

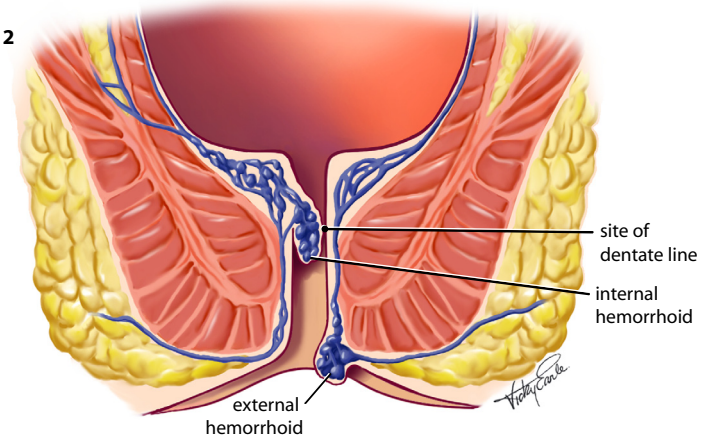

Because the condition is associated with, or caused by, high anal sphincter pressure, relaxing the sphincter with muscle relaxants such as Nitroglycerin or Diltiazem® cream is very helpful in pain relief and healing. Your physician may prescribe 5% Xylocaine® ointment and recommend Sitz baths and half of each day lying flat and when the patient is seen in 2 to 3 weeks the condition has resolved and banding can be performed.

© 2008 Iain Cleator, The Cleator Clinic. All rights reserved.